

## Trismus due to bilateral mandibular coronoid hyperplasia.

AJ Gibbons, AJ Byrne, SJ Key

### ABSTRACT

**Bilateral mandibular coronoid hyperplasia is a rare cause of restricted mouth opening. Diagnosis of the condition prior to general anaesthetic is essential, as oral intubation may be impossible. The reported case illustrates the role of computed tomography in assessment of the disorder and effective treatment by coronoidectomy.**

### Introduction

Bilateral mandibular coronoid hyperplasia is a condition of insidious onset characterised by a painless limitation of mouth opening. The enlarged coronoid processes impinge on the zygomatic arches causing a physical obstruction to mandibular movements. Diagnosis of the condition is confirmed by an orthopantomograph (OPG). Computed tomography further details the region's anatomy and may reveal additional zygomatic pathology.

The following case report demonstrates the dramatic improvement in mouth opening which can be achieved through surgical intervention.

### Case Report

A 28 year old male Sergeant of European descent was referred to the Department of Oral and Maxillofacial Surgery, Princess Alexandra's Royal Air Force Hospital, Wroughton, for assessment of his restricted mouth opening. The patient first noticed the problem at 16 years of age and had

previously been unsuccessfully treated at a dental hospital with bite raising and interdental screw appliances.

On clinical examination the patient's inter-incisal opening was limited to 15mm and the top of the right coronoid process could be palpated above the zygomatic arch. An OPG (Figure 1) showed unequal enlargement of the coronoid processes. Three-dimensional computed tomography (3-D CT) images were taken to detail more clearly the morphology and relationships of the coronoid processes (Figure 2). These revealed a large extosis of the right zygomatic arch at the point of contact with the coronoid process (Figure 3).

Coronoidectomies were subsequently performed under general anaesthetic using a fiberoptic technique to establish endotracheal intubation. In view of the gross enlargement of the coronoid process and additional zygomatic pathology, an external temporal/pre-auricular approach was made to the right side. The zygomatic arch was sectioned, pedicled from the masseter and following coronoidectomy, reconstituted with mini-plates. Opening improved to 30mm allowing an intra-oral approach to coronoidectomy on the left side.

Post-operatively the patient could open to 40mm and was encouraged to use an interdental screw appliance to help prevent fibrosis. Histological examination of the excised coronoid revealed normal mature bone, consistent with a diagnosis of hyperplasia.

Wg Cdr A J Gibbons  
MA (CANTAB),  
FDSRCS, FRCS, RAF  
Specialist Registrar Oral  
& Maxillofacial Surgery

Dr A J Byrne  
MRCP, FRCS  
Consultant Anaesthetist

Mr S J Key  
FDSRCPS, FRCS  
Staff Grade Oral &  
Maxillofacial Surgery

Morrison Hospital,  
Swansea, S. Wales,  
SA6 6NL

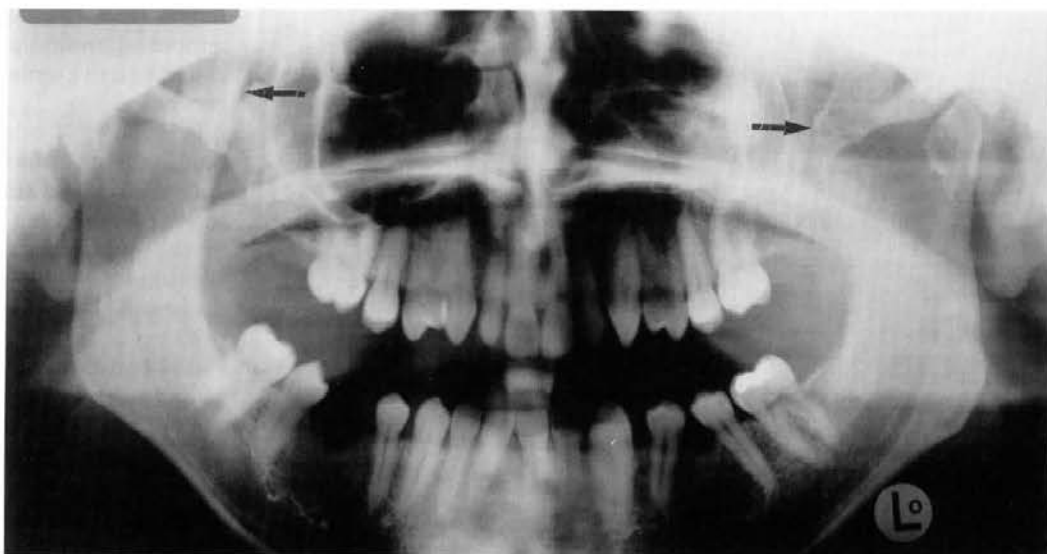

Fig 1. Panoramic radiograph showing coronoid process (arrowed).




Fig 2. 3-D CT scan of right coronoid process elongation.

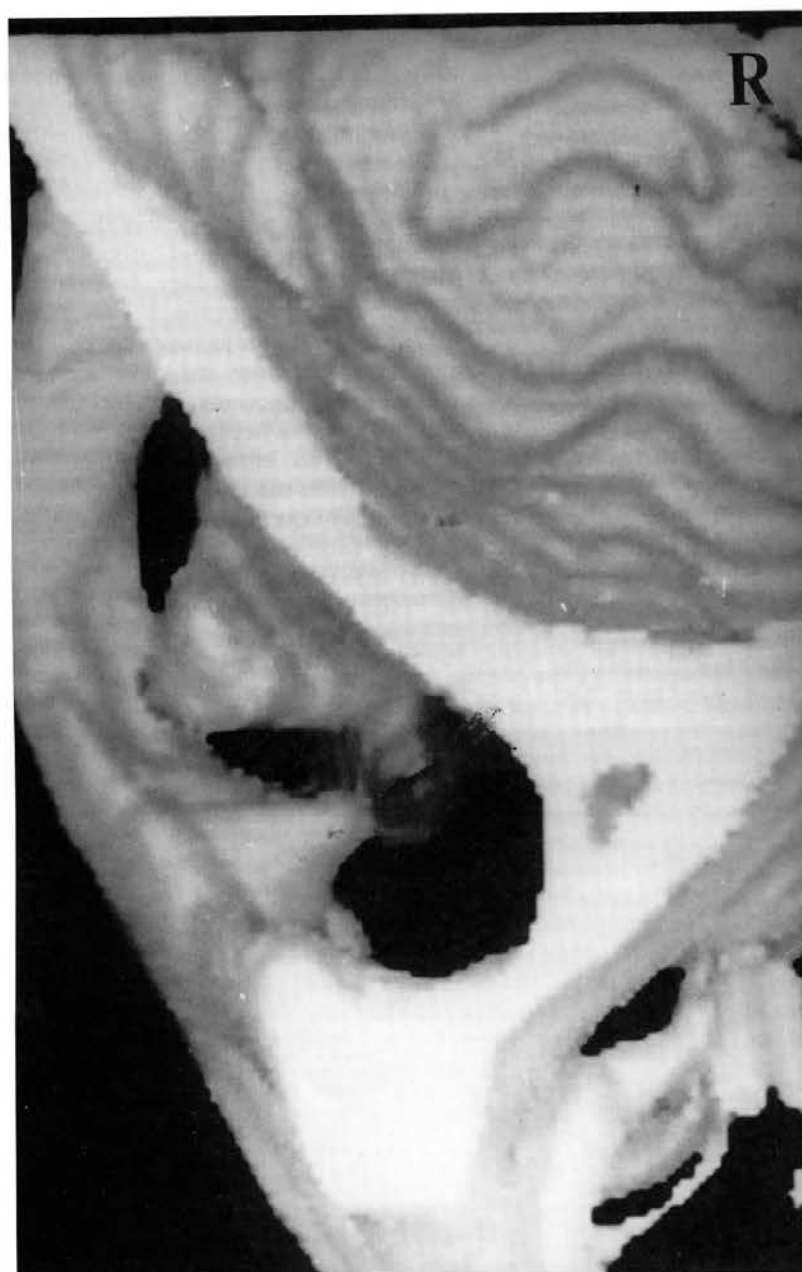


Fig 3. 3-D CT scan showing right zygomatic arch extosis (arrowed).

The patient's improved opening has remained stable and he has no evidence of regrowth of the coronoid processes.

### Discussion

Bilateral mandibular coronoid is insidious in onset and not associated with pain or deformity. Therefore, patients may be unaware that they have limited mouth opening (1). The condition may be life threatening. Rusconi and Brusatti (2) in 1963 reported a patient involved in a road traffic accident where tracheal intubation proved impossible and an emergency tracheostomy was required. Subsequently a diagnosis of bilateral mandibular coronoid hyperplasia was established as the cause of his restricted mouth opening.

The aetiology of bilateral mandibular coronoid hyperplasia remains unclear. The condition is more common in males, with an onset in puberty indicating a possible endocrine influence (1). In animal models hyperactivity of the temporalis muscle triggered by hypomobility of the temporomandibular joint has been found to cause reactive enlargement of the coronoid processes (3).

Previously bilateral and unilateral mandibular coronoid hyperplasia have been defined as two distinct entities (1). However, many cases display at least some abnormality of the opposite side and it is likely that a continuous spectrum exists, from the pure unilateral case to complete involvement of both processes (4).

Bilateral mandibular coronoid hyperplasia may not be as rare as formerly believed. Of the 88 cases of the disorder in the Western literature 23 were identified at one unit alone (4). In a review of 163 patients with limited opening of the mandible, Isberg *et al* (5) found that 5% cases were due to enlargement of the coronoid process. As the

condition is neither painful nor associated with facial deformity, patients often fail to seek advice. Clinicians unfamiliar with the disorder may also fail to consider the diagnosis.

The Levandoski pantographic analysis of OPGs may be used to determine if a coronoid process is enlarged (6). When the ratio of the length of the coronoid process to the condylar process on the radiograph is greater than 1.1 a diagnosis of coronoid process hyperplasia is suggested and further investigation of the condition is warranted.

Computed tomography accurately demonstrates the detailed anatomy of the region including the precise extent of the enlarged coronoid processes and their relationships to the zygomatic arches. This information assists the surgeon in evaluating whether an external temporal/pre-auricular or intra-oral approach to coronoidectomy is required.

Surgery is the only successful form of treatment. Awake fibreoptic intubation is the safest anaesthetic technique to use on patients diagnosed with this condition. In cases of extreme trismus, an external temporal/pre-auricular approach allows better surgical access to the region and avoids restrictive intra-oral scarring.

Regrowth of the coronoid processes following intra-oral coronoidectomies may occur. This may be due to regeneration of bone with haematomas (7) or the influence of abnormal temporalis muscle fibres (4). Consequently, long term review of treated patients is recommended.

When assessing the airway prior to surgery, if there is restricted mouth opening, mandibular coronoid hyperplasia although rare, should be considered in the differential diagnosis.

### Acknowledgments

We thank Air Commodore T W Negus, Consultant in Oral Maxillofacial Surgery for permission to present his patient, Air Commodore J Reid, Director of Dental Services (RAF) for his consent to publish this paper.

### References

1. Rowe NL. Bilateral development hyperplasia of the mandibular coronoid process. *Br J Oral Surg* 1963; **1**: 90-104.
2. Rusconi L, Bruscati R. Restricted opening of the mouth from symmetrical bilateral hyperplasia of the coronoid processes. *J Oral Surg* 1974; **32**: 452-456.
3. Isberg AM, McNamara Jr JA, Carlson DS, Isacson G. Coronoid process elongation in rhesus monkeys (*Macaca mulatta*) after experimentally induced mandibular hypomobility. *Oral Surg Oral Med Oral Pathol* 1990; **70**: 704-710.
4. McLoughlin PM, Hopper C, Bowley NB. Hyperplasia of the mandibular coronoid process: An analysis of 31 cases and a review of the literature. *J Oral Maxillofac Surg* 1995; **53**: 250-255.
5. Isberg A, Isacson G, Nah KS. Mandibular coronoid process locking. A prospective study of frequency and association with internal derangement of the temporomandibular joint. *Oral Surg Oral Med Oral Pathol* 1987; **63**: 275-279.
6. Kubota Y, Takenoshita Y, Takamori K, Kanamoto M, Shirsuna K. Levandoski pantographic analysis in the diagnosis of hyperplasia of the coronoid process. *Br J Oral Maxillofac Surg* 1999; **37**: 409-411.
7. Smyth A G, Wake MJC. Recurrent bilateral coronoid hyperplasia: an unusual case. *Br J Oral Maxillofac Surg* 1994; **32**: 100-104.

**JRAMC**

## **Trismus due to bilateral mandibular coronoid hyperplasia.**

A J Gibbons, A J Byrne and S J Key

*J R Army Med Corps* 2001 147: 311-313

doi: 10.1136/jramc-147-03-11

---

Updated information and services can be found at:

<http://jramc.bmj.com/content/147/3/311>

---

*These include:*

### **Email alerting service**

Receive free email alerts when new articles cite this article. Sign up in the box at the top right corner of the online article.

---

### **Notes**

---

To request permissions go to:

<http://group.bmj.com/group/rights-licensing/permissions>

To order reprints go to:

<http://journals.bmj.com/cgi/reprintform>

To subscribe to BMJ go to:

<http://group.bmj.com/subscribe/>